

Chapter 12

Hydrops fetalis

HYDROPS FETALIS

Hydrops is defined by abnormal accumulation of serous fluid in skin (edema) and body cavities (pericardial, pleural, or ascitic effusions).

Prevalence

Hydrops fetalis is found in about 1 per 2,000 births.

Etiology

Hydrops is a non-specific finding in a wide variety of fetal and maternal disorders, including hematological, chromosomal, cardiovascular, renal, pulmonary, gastrointestinal, hepatic and metabolic abnormalities, congenital infection, neoplasms and malformations of the placenta or umbilical cord. Hydrops is classically divided into immune (due to maternal hemolytic antibodies) and non-immune (due to all other etiologies). With the widespread introduction of immunoprophylaxis and the successful treatment of Rhesus disease by fetal blood transfusions, non-immune causes have become responsible for at least 75% of the cases, and make a greater contribution to perinatal mortality. While in many instances the underlying cause may be determined by maternal antibody and infection screening, fetal ultrasound scanning, including echocardiography and Doppler studies, and fetal blood sampling, quite often the abnormality remains unexplained even after expert post-mortem examination.

Prognosis

Although isolated ascites, both in fetuses and neonates, may be transitory, the spontaneous resolution of hydrops has not been reported and the overall mortality for this condition is about 80%.

Ultrasound Diagnosis

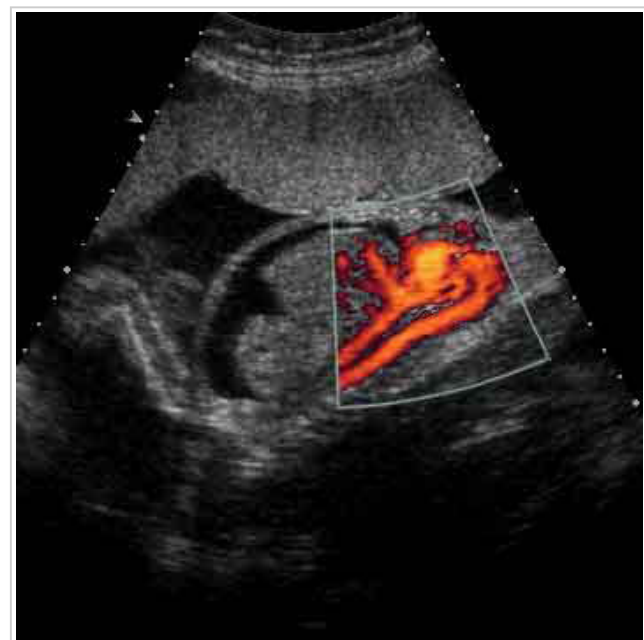
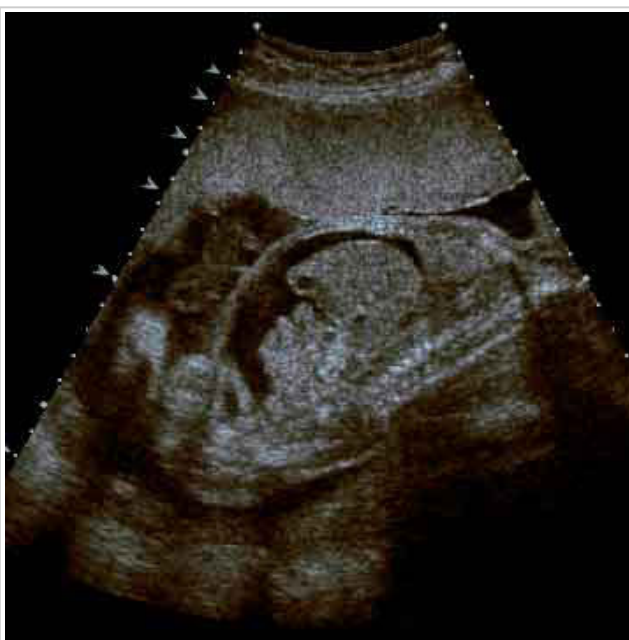
Figure 1 - longitudinal view, abnormal accumulation of serous fluid at the body cavities (pericardial, pleural, or ascitic effusions).

Figure 2 - longitudinal view, abnormal accumulation of serous fluid at the body cavities (pericardial, pleural, or ascitic effusions) & Color doppler energy flow.

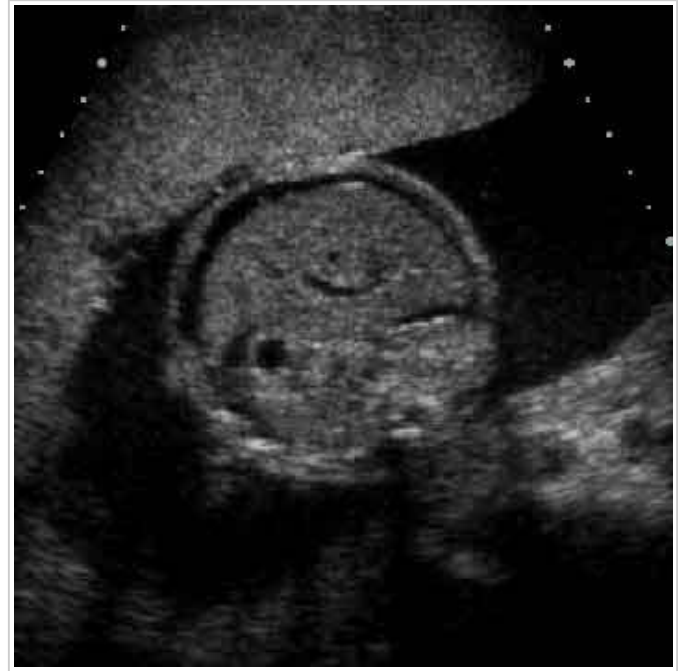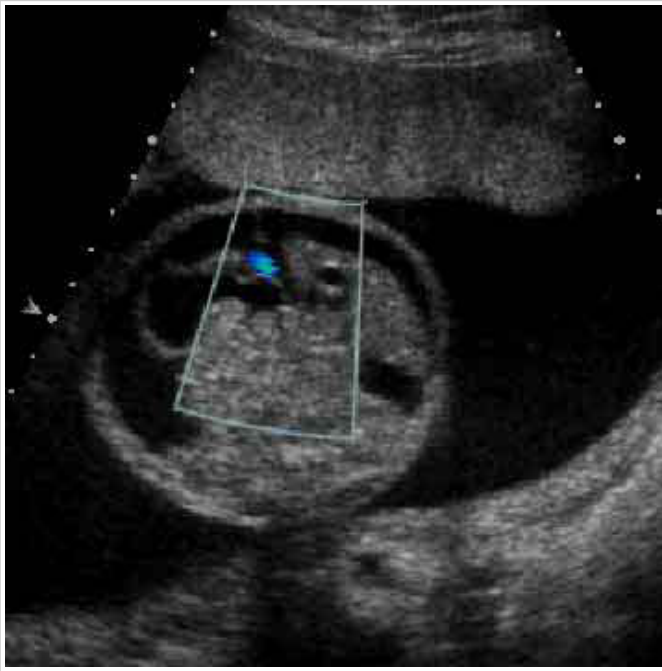


Figure 3 - transverse view, at the stomach and bowel level, with abnormal accumulation of serous fluid at the abdomen or ascitic effusion.

Figure 4 - transverse view, at the stomach level, with abnormal accumulation of serous fluid at the abdomen or ascitic effusion.

Fetal therapy

Immune hydrops can be successfully treated by blood transfusions to the fetus. Such treatment often results in reversal of hydrops and the survival rate is about 80%. Fetal therapy can also successfully reverse some types of non-immune hydrops, such as fetal tachyarrhythmias (by transplacental or direct fetal administration of antiarrhythmic drugs), pleural effusions (by pleuro-amniotic shunting), urinary ascites (by vesico-amniotic or peritoneal-amniotic shunting), parvovirus B19 infection or severe fetomaternal hemorrhage (by fetal blood transfusions), diaphragmatic hernia, cystic adenomatoid malformation of the lungs and sacrococcygeal teratoma (by open fetal surgery), and the recipient fetus in twin-to-twin transfusion syndrome (by endoscopic laser coagulation of the communicating placental vessels).